


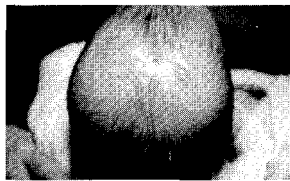
MINOR ANOMALIES

Minor anomalies are unusual external physical features which do not inhibit a major function of the body. Most of the normal population has one or two minor anomalies inherited from a parent. Occurrence of three or more minor anomalies which


are not present in other family members *may* indicate an individual has a syndrome and/or major malformation. Medical geneticists use minor anomalies as clues in establishing diagnoses for their patients. If you observe three or more new occurring minor anomalies in an individual, a referral for genetic evaluation is appropriate.



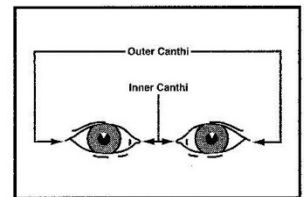
Low Posterior Hairline:
Low hair growth on nape of neck, especially at lateral borders




Multiple Hair Whorls:
More than one hair whorl; thought to be more significant with increasing distance between the whorls




Synophrys:
A condition in which the two eyebrows grow together




Ocular Hypertelorism:
Abnormal width between the eyes (increased width)



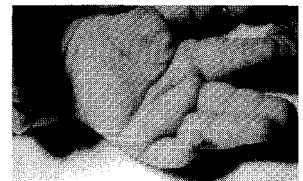
Epicanthal Folds:
Folds of skin on the inner canthus (corner) of the eye



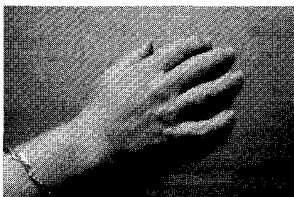
Ear Tag:
Nodule of skin which may contain a core of cartilage; may be preauricular and/or auricular




Low-Set & Rotated Ears:
The top of the ear is below an imaginary line that extends backward from the corner of the eye. Rotation occurs when the angle is more than ten degrees from the perpendicular.



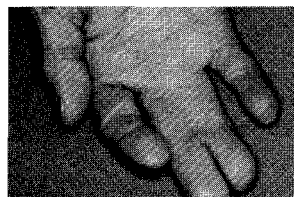
Simian Crease:
Single palmar crease



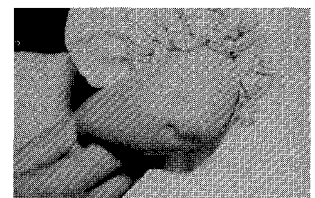
Clinodactyly:
Permanent curve of a finger, most commonly an inward curve of the distal tip of the 5th finger.



Pectus Excavatum:
Sternum abnormally depressed.



Syndactyly:
A fusion of fingers or toes.



Deep Dimples:
Usually at prominent bony joints

Other common minor anomalies which are significant when performing a genetics physical exam include:

- Widow's peak (frontal hair pattern)
- Short palpebral fissures
- Upward /downward lateral slant of palpebral fissures
- Abnormal eyebrows
- Small /prominent ears
- Lack of ear lobes or unusual folds of the ear
- Broad / webbed neck
- Unusual /deep crease in palms of hands and soles of feet
- Short/broad or narrow /hyperconvex fingernails and toenails
- Polydactyly /rudimentary polydactyly
- Large gap between the first and second toes
- Short first metatarsal with flexion of first toe (drawn up toe)
- Hyperextensibility of joints
- Prominent heels
- Nail hypoplasia
- Cafe au lait spots on the skin
- Depigmented spots on the skin (white spots)
- Body hirsutism (hairy)
- Pectus excavatum (sternum abnormally depressed)
- Punched out scalp lesions (usually on the crown)
- Blue sclera
- Brushfield spots
- Rocker bottom feet

References:

Marden, Phillip M.; Smith, David W.; and McDonald, Michael J., "Congenital Anomalies in the Newborn Infant, Including Minor Variations," *Journal of Pediatrics*. 64:357, 1964.

Smith, David W.; and Gong, Bradley T., "Scalp Hair Patterning as a Clue to Early Brain Development," *Journal of Pediatrics*. 83:374, 1973.

Smith, David W.; and Jones, Kenneth Lyons, *Recognizable Patterns of Human Malformation*. Philadelphia: W. B. Saunders Company, 1988.

Genetics Program

Newborn Screening Unit

Texas Department of State Health Services

1100 West 49th Street, Austin, Texas 78756

1-800-252-8023 ext. 3957